

# A surgical management of melanotic progonoma tumor of Infancy – A case report

Shilpa Hazare<sup>1</sup>, Isha Hazarey<sup>2</sup> Jitendra Hazarey<sup>3\*</sup>, Pritish Bhansali<sup>3</sup>, Vishal Mahant<sup>3</sup>, Rashiqua Sadiya<sup>3</sup>

1

1. Dept. of Pediatrics & Neonatology, Getwell Hospital, Nagpur, India  
2. Jawaharlal Nehru Medical College, Sawangi, Wardha, India  
3. Getwell Hospital, Nagpur, India

\*Corresponding author  
Dr. Jitendra Hazarey, MBBS, MS, MCh  
Consultant and Pediatric surgeon at Getwell Hospital, Nagpur, India

Email: jitendrahazare1968@gmail.com

## ABSTRACT

Melanotic neuroectodermal tumors (MNTI) also known as retinal anlage tumor and melanotic progonoma is highly aggressive lesion found in children within 6 months of age. It is a relatively rare pathology and is also rare to metastasise. MNTI can be seen in various locations within the oral cavity, the most common being maxillary jaw. Presently advent technology of has enabled us to utilise various different modalities ranging from radical excision, incomplete resection to chemotherapy. Chemotherapy is preferred in cases of contraindication of surgical approaches. The results regarding each approach can be mixed, successful tumour regression or complete failure. The present article focuses on successful subtotal excision of MNTI in a one year old infant.

**Keywords:** case report, Lump in the maxilla, maxilla tumor, marginal mandibulectomy, melanotic neuroectodermal tumor of infancy.

## INTRODUCTION:

Melanotic prognoma is also known as a melanotic neuroectodermal tumor of infancy (MNTI), which predominantly affects the anterior maxilla of newborns.

Prognoma of the neural crest, also known as melanotic neuroectodermal tumor of infancy (MNTI), affects the anterior maxilla of infants which is associated with severe adverse effects like morbidity and mortality (1). The nomenclature history of maxillary congenital melanocarcinoma ranges from melanotic prognoma (Krompecher in 1918) to melanotic neuroectodermal tumor of infancy (Borello and Gorlin, 1963) (2-3).

Majority of the MNTI occur in the craniofacial bones, especially in the maxilla (70%) and mandible (10%). Besides the cranium (10%), other sites such as the brain (1%), skin, uterus, epididymis and mediastinum (1-4%) were also affected by MNTI. More than 90% of cases manifest during the first year of life with slight prediction towards male population (4, 5).

Despite of major advances in medical and instrumental therapy, MNTI still constitute 14- folds higher mortality rate, among infants with recurrence rates of about (20-25% (6-9).

In addition, delayed diagnosis can result in tumours encroaching on adjacent vital structures, which may necessitate a radical resection, resulting in higher morbidity rates.

Generally, treatment suggested for MNTI is surgical excision, radiotherapy in conjugation with surgery and chemotherapy with long-term follow-up.

In this case, a benign MNTI was treated with surgical excision and resulted in successful recovery. The present case is of academic as well as clinical interest because so far only 500 cases reported from 1986. Hence, we have backed up the case report with literature review of all the cases reported in past five years to know the best possible management of the disease interest of pediatric health.

### Case Report:

A 2-month-old female patient was reported to (hospital name) on (date, Nagpur dist. Nagpur with a chief com-

plaint of rapidly increasing painless, firm mass underlying an intact epithelial surface in the maxilla. Symptom such as, swelling of the maxilla had been observed by her parents a month before.

However, the patient had no previous history of fever or any difficulties.

Physical examination revealed that, patient had a disfigured face and protruded upper lip. A firm swelling measuring 1 cm was detected on the anterior maxilla.

A lump in the maxilla region was attached to a small tooth. However, the patient had no feeding difficulty.

#### Investigation-

A wide surgical excision was performed by injecting anaesthetic and removing the tooth buds affected by the lesion to avoid local recurrence.

#### Clinical examination-

The specimen consists of a spherical soft tissue mass of blue and black discoloration, measured 1cm in diameter. The tumor was covered with ulcerated mucosa to the corner of the lesion. Its cut surface was soft and had a small tooth attached to one pole. (Fig 1)

#### Microscopic examination-

Cellular tumor was composed of round neuroblast like cells arranged in a nest and alveolar fashion amidst desmoplastic tissue. The cells had scanty cytoplasm and round nuclei with fine nuclear chromatin. Interspersed cells contained brownish pigment. Low mitotic activity was seen. However, necrosis was completely absent. (Fig 2)

#### Radiographic examination-

A primitive neuroectodermal tumour was revealed on computed tomography (CT) investigation.

#### Diagnosis-

Differential diagnosis of MNTI includes various pediatric small round cell neoplasms such as neuroblastoma, Ewing's sarcoma, peripheral neuroepithelioma, rhabdomyosarcoma and peripheral primitive neuroectodermal tumor, desmoplastic small round cell tumor, malignant melanoma and lymphoma (10).

Based on these findings, the tumor was diagnosed as MNTI.

### Immunohistochemistry –

DAKO Autostainer Link 48 (Agilent Technologies, California) was used for immunohistochemistry procedures. Tumor tissue was stained with pancytokeratin (Pan-CK), HMB45, Melan-A, synaptophysin (Syn), chromogranin (CgA), Ki-67, vimentin (Vim), neuron-specific enolase (NSE), S100 and desmin (Des). However, AEC+ High Sensitivity Substrate Chromogen kit (K3469, Agilent Technologies, California) was used to visualize the signals.

### Treatment-

Management of this rapid grown, locally aggressive tumour entails complete excision with a safety margin of 0.5–1 cm. (11-14). (Fig 3)

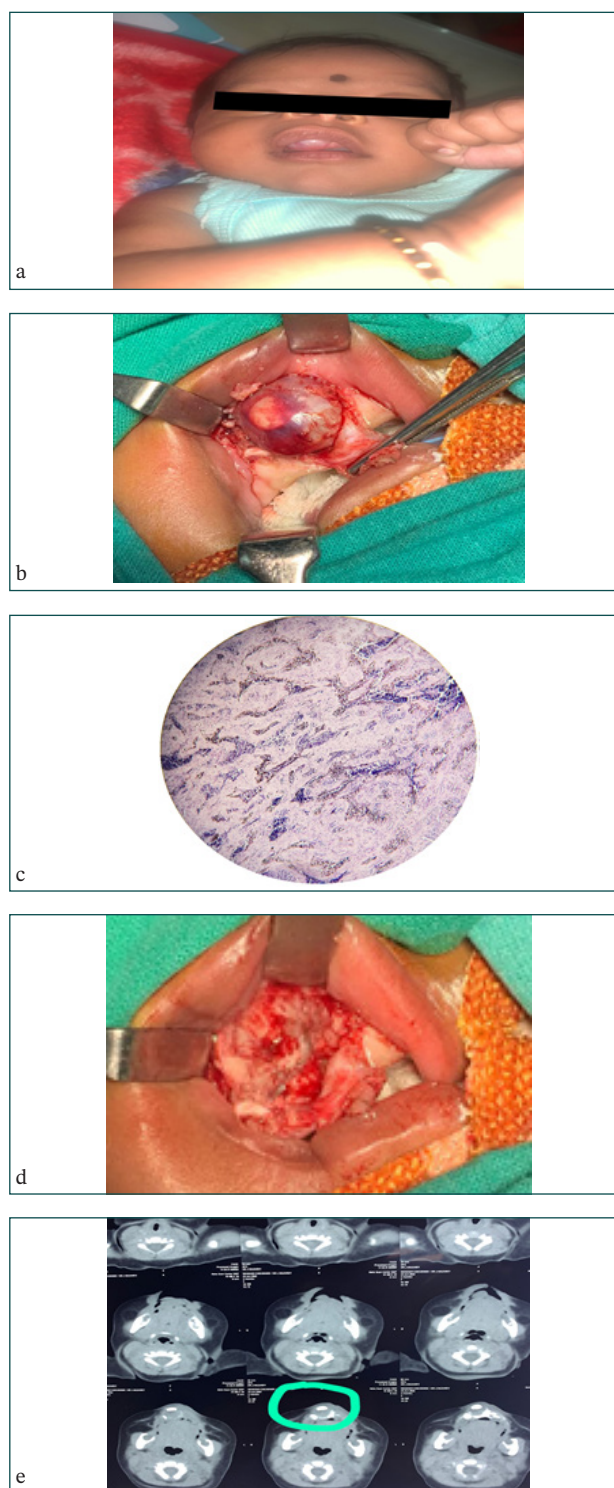
### Discussion:

Primordial origin of MNTI governs the variety of other names associated with it, such as melanotic epithelial odontome, odontogenic hamartoma, melanotic adamantinoma, melanoameloblastoma, retinal anlage tumour, pigmented epulis of neuroepithelial origin, melanotic progonorna, pigmented ameloblastoma, congenital melanocarcinoma, pigmented congenital epulis, retinoblastic teratoma and neuroectodermal progonoma. The variety of names are reflective of its uncommon occurrence and non-standardised histogenesis.

Below table shows brief history of MNTI in last 5 years. Despite its benign nature, MNTI can recur up to 20% of the times. This pathological condition must therefore be diagnosed and treated early to avoid serious consequences. However, recurrence rates of up to 60% has been reported by some other studies. It was imperative to learn about early detection of diseases in order to reduce the risk of such a devastating illness, which is due to its early age of involvement and rapid spread of the disease.

Despite this, Kruse-Lösler et al. reported that this tumor carries the highest recurrence risk among all mandibular tumors, which is up to 33%, compared to maxillary lesion, however, show lesser percentage of recurrence around 19.3% (9, 11, 15, 16, 17).

Liu et al. explained in 2004 that the aggressive expansion of the lesion might block the infant's airway, they



**Figure 1.** Above figures shows, pre-operative extraoral view (figure-a), preoperative intra oral view (figure-b), nests of round cells and pigment laden cells in stroma Magnification 10X (figure-c), post-operative intra-oral view(figure-c), radiographic image of MNTI (figure-d)

**Table 1.** Brief history of MNTI in last 5 years.

Author	Number of cases	Sex	Age of first symptoms (month)	Age at surgery (month)	Location	Largest diameter (cm)	Radiologic findings	Clinical impression	Management	Follow Up (month)
Maj man mohan harjai*, dr ashok kumar sharma+	1	Male infant	Since birth	4	Left anterior maxillary gingival vestibule.	2.5 x 2,0 x 1.5 cm	Radiograph of the maxilla showed a soft tissue mass arising from the canine region of the left alveolus.	Cyst	Local excision	No recurrence
Rajendra Reddy E et.al	1	NA	2	4	Right back tooth region of maxilla.	3.2 cm x 2.1 cm x 2.3 cm	Diffuse osteolytic radiolucent lesion	Tumor	Biopsy	(6 Month) no evidence of recurrence
Shady A.Moussa et.al	1	Male infant		6	Anterior alveolar ridge of the mandible.	30x20x20 mm	Uniform multicentric osteolytic lesion	Tumor	Biopsy	(12 month) No evidence of recurrence
Shady A.Moussa et.al	2	1.Female		3	Anterior maxilla	3x4cm	Well-defined osteolytic lesion encroaching on the right anterior maxillary wal	Tumor	Incisional biopsy	(3 years) Recurrence of the lesion occurred four months later
		2.Female		4	Left maxilla	4x5cm	Expansile lesion of the left maxilla	Tumor	Incisional biopsy	(18 months) No recurrence
Jose David Mota Gamboa et.al	2	1		16	N the right temporal bone	3.8 x 2.7 x 1.5 cm,	Destructive lytic and hyperdense bone lesion	Tumor	Excisional biopsy	(6 years) No recurrence
		2		4	Left temporal region	3 cm	Delimited radiodense lesion	Tumor	Biopsies	(12 month) No evidence of recurrence

demonstrated 90% of cases of this disease occur in infants under the age of 1 year (18).

A large, polygonal epithelioid cell characterized by granular brown pigmentation within the cells and positive vimentin, cytokeratin, HMB45, and cytokeratin along with an elongated neuroblast-like cell surrounded by fibrous tissue, as well as fibroblasts and blood vessels are found in this tumour's histology (9, 12, 19).

MNTI is somewhat rare in the literature, but most authors agree that wide excision with clear margins has the gold standard.

In present case, surgical excision was done and there was no recurrence. A safety margin of 0.5–1 cm has been reported to suffice in extensive lesions. An analysis conducted by Rachidi et al showed no difference between patients who received curettage only and those who received resection.

In cases of recurrence, malignant transformation or giant tumours which are clinically inoperable, in such case, adjuvant or neoadjuvant therapies may be used (9, 11, 14, 16).

Adjuvant and neoadjuvant treatment options are more preferable in cases of contraindication of surgical approaches in larger lesions that cannot be resected primarily and ones associated with recurrence and malignant transformation rate (9, 11, 12, 14).

Several authors emphasize the importance of annual MRIs of the tumour site along with postoperative follow-up appointments due to this high rate of local recurrence (11, 16, 17).

Therefore, present case report was written with a view to shed light upon the rarest condition of MNTI and review on its past few years history.

### Conclusion:

Male infants are mainly affected by MNTI, an extremely rare tumor of the maxilla. It is helpful to distinguish small round cell tumours from melanin-containing tumours by their histopathological features and immunohistochemical profiles.

In the present study, no BRAF V600E mutation was detected in MNTI and further research is required. Oppos-

ing studies are present regarding the factors leading to local recurrence, hence leading to interpretation of inconclusive results necessitating a regular follow up.

### REFERENCES

1. Almomani MH, Rentea RM. Melanotic Neuroectodermal Tumor Of Infancy. [Updated 2022 May 8]. In: StatPearls [Internet]. Treasure Island (FL): StatPearls Publishing; 2022 Jan-.
2. Borello ED, Gorlin RJ (1966) Melanotic neuroectodermal tumor of infancy. A neoplasm of neural crest origin. *Cancer* 19: 196-205. [Crossref]
3. Krompecher E (1918) Zur Histogenese und morphologie der adimantinome und sonstiger kiefergeschwülste. *Beitr Path Anat Allg Pathol* 64: 165-197.
4. Antunes AC, Freitas RM, Oliveira PP, Reboucas RG (2005) Melanotic neuroectodermal tumor of infancy. *Arq Neuropsiquiatr* 63: 670-672.
5. Kumari RN, Sreedharan S, Balachandran D (1993) Melanotic neuroectodermal tumor of infancy: a case report. *Am J Surg Pathol* 17: 566-573. [Crossref]
6. Pontes FSC, de Souza LL, Uchôa DCC, Joaquim AMC, do Nascimento LS, da Mata Rezende DDS, Pontes HAR. Melanotic neuroectodermal tumor of infancy of the jaw bones: Update on the factors influencing survival and recurrence. *Head Neck*. 2018 Dec;40(12):2749-2756. [PubMed]
7. Ren Q, Chen H, and Wang Y, et al (2019) Melanotic neuroectodermal tumor of infancy arising in the skull and brain: a systematic review *World Neurosurg* 130 170–178 <https://doi.org/10.1016/j.wneu.2019.07.017> PMID: 31295620
8. Santos HBP, Luna AHB Goes PEM, and Sverzut AT, et al (2018) Estudo clínico e imuno-histoquímico de tumor neuroectodérmico melanocítico da infância em maxila Einstein (São Paulo) 16(2)
9. Kruse-Lösler B, Gaertner C, and Bürger H, et al (2006) Melanotic neuroectodermal tumor of infancy: systematic review of the literature and presentation of a case *Oral Surg Oral Med Oral Pathol Oral Radiol Endod* 102(2) 204–216 <https://doi.org/10.1016/j.tripleo.2005.08.010>

10. Gaiger de Oliveira M, Thompson LD, Chaves AC, Rados PV, da Silva Lauxen I, Filho MS. Management of melanotic neuroectodermal tumor of infancy. *Ann Diagn Pathol* 2004;8:207-12.
11. A. Azari, D. Petrisor, J. Wright, G.E. Ghali Metastatic melanotic neuroectodermal tumor of infancy: report of a case and review of the literature *J. Oral Maxillofac. Surg.*, 74 (December (12)) (2016), pp. 2431-2440.
12. K. Higashi, T. Ogawa, M. Onuma, H. Usubuchi, Y. Imai, I. Takata, H. Hidaka, M. Watanabe, Y. Sasahara, S. Koyama, S. Kure Clinicopathological features of melanotic neuroectodermal tumor of infancy: report of two cases *Auris Nasus Larynx*, 43 (August (4)) (2016), pp. 451-454.
13. B. Kruse-Lösler, C. Gaertner, H. Bürger, L. Seper, U. Joos, J. Kleinheinz Melanotic neuroectodermal tumor of infancy: systematic review of the literature and presentation of a case *Oral Surg. Oral Med. Oral Pathol. Oral Radiol. Endodontol.*, 102 (August (2)) (2006), pp. 204-216.
14. J.M. Davis, M. DeBenedictis, D.K. Frank, M.E. Lessin-Melanotic neuroectodermal tumor of infancy: a wolf in sheep's clothing *Ann. Otol. Rhinol. Laryngol.*, 124 (February(2)) (2015), pp. 97-101.
15. Saleh Rachidi, et al. Melanotic neuroectodermal tumor of infancy: a systematic review *J. Oral Maxillofac. Surg.*, 73 (10) (2015), pp. 1946-1956.
16. M.R. Emmerling, T.A. York, J.F. Caccamese Melanotic neuroectodermal tumor of infancy (MNTI): case report and review of management *J. Oral Maxillofac. Surg.* (2018).
17. Sefa Kaya, et al. Melanotic neuroectodermal tumor of infancy: report of two cases and review of literature *Int. J. Pediatr. Otorhinolaryngol.*, 52.2 (2000), pp. 169-172
18. Liu Z, Li M, Tang X, et al. Melanotic neuroectodermal tumor of infancy in ovary: a rare case report. *Medicine* 2019;98:e18181.
19. D.J. Fowler, J. Chisholm, D. Roebuck, L. Newman, M. Malone, N.J. Sebire Melanotic neuroectodermal tumor of infancy: clinical, radiological, and pathological features *Fetal Pediatr. Pathol.*, 25 (January (2)) (2006), pp. 59-72.