

Benign Multi-Cystic Peritoneal Mesothelioma: A Case Report

Ali Shaghghi^{1*}, Roya Yousefian¹

ABSTRACT

108

1. Zanzan University Of Medical Sciences, Mousavi Hospital, Zanzan, Iran.

***Corresponding Author:**

Ali Shaghghi, MD.

Assistant professor of Surgery, Zanzan University Of Medical Sciences, Mousavi Hospital, Zanzan, Iran.

Tel: (+98)9123894291

Email: ali.shaghghi71@yahoo.com

Benign multicystic peritoneal mesothelioma (BMPM) is a rare disorder that occurs predominantly in reproductive-aged women. A 42-year-old male referred to our emergency department in Mousavi Hospital of Zanzan University, suffering from diffuse abdominal pain. He mentioned a history of operation two years ago, during which cystic tumors had been removed from his abdomen.

A cytoreductive surgery was performed. The pathologic study confirmed the diagnosis of BMPM and immunohistochemical analysis verified the negative expression of CD34 marker and positive expression of calretinine in the cyst lining. Preoperative diagnosis of BMPM is difficult and definitive diagnosis requires histological evaluation of the specimen. Due to the rarity of BMPM, the need for familiarity with this benign but aggressive tumor is felt.

Keywords: Cytoreductive surgery, Peritoneal cysts, Benign mesothelioma

BCCR

2019; 11(2):108-111

www.bccrjournal.com

INTRODUCTION:

The incidence of BMPM (also known as multi-locular peritoneal inclusion cyst) is approximately one per 1,000,000 and it comprises roughly one-fifth to one-third of all mesotheliomas¹. This lesion often presents with abdominal pain, palpable mass, or both. Mesothelioma is a neoplasm that originates from the cells lining the pleura, pericardium or peritoneum. The tumor is composed of spindle cells or fibrous tissue, which may enclose gland-like spaces lined by cuboidal cells². This lesion frequently occurs in women during their reproductive years and is common in patients with a history of previous abdominal surgery, pelvic inflammatory disease and endometriosis³. However, there have been some reports of this disease in men and children.

Case Presentation

In March 2017, a 42-year-old male was admitted to the emergency department in Mousavi Hospital complaining of diffuse abdominal pain (with no radiation) and mild weight loss. There were no other associated symp-

toms. The patient mentioned a history of an appendectomy six years ago and a midline laparotomy two years later. During the latter operation cystic masses had been removed and omentectomy had been performed. For the past two years, the patient had suffered from chronic abdominal pain. On physical examination, vital signs were normal (except mild tachycardia). Abdominal distention and scars secondary to his previous surgeries were noticeable. A painful mass was palpated in the lower abdomen. Ultrasonography revealed the presence of numerous cystic lesions in the abdomen and pelvic cavity with different sizes and mixed echo. These lesions were spongiform. Spiral C.T scan also confirmed the sonographic findings (**Fig.1**). A cytoreductive surgery (R1 resection) was performed and multiple cysts with varying sizes between 2 and 200 mm were removed without resection of solid organs and bowels (**Fig.2**). We sent specimens to the pathology laboratory. The immunohistochemical analysis documented negative expression of CD34 marker and positive expression of calretinine in the cyst lining. The previous pathology report also confirmed the diagnosis of BMPM. The patient is currently symptomless and there have been no signs of recurrence up until now.

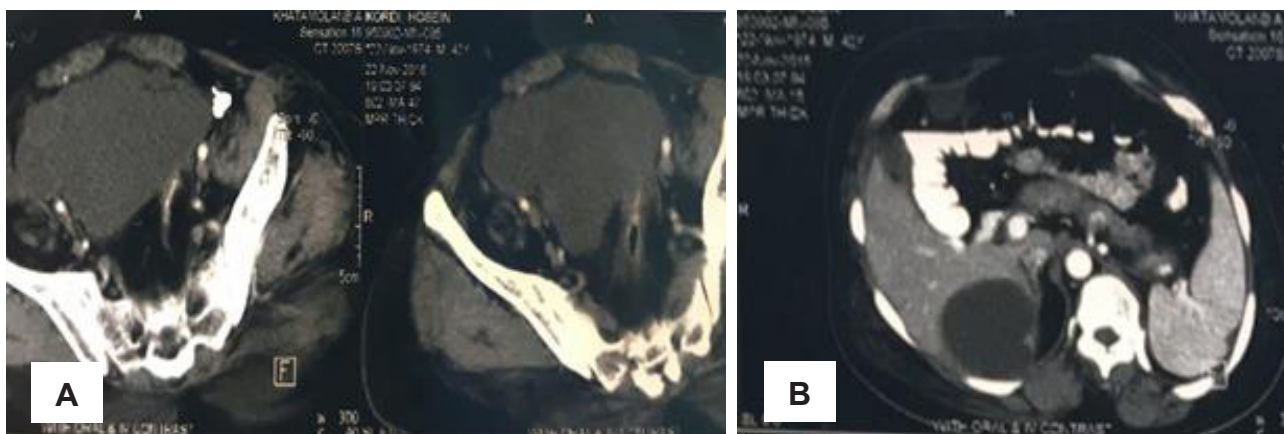


Figure 1. Computer tomographic scan revealed huge mass in the pelvic cavity (A) and a mass in the subhepatic area (B).

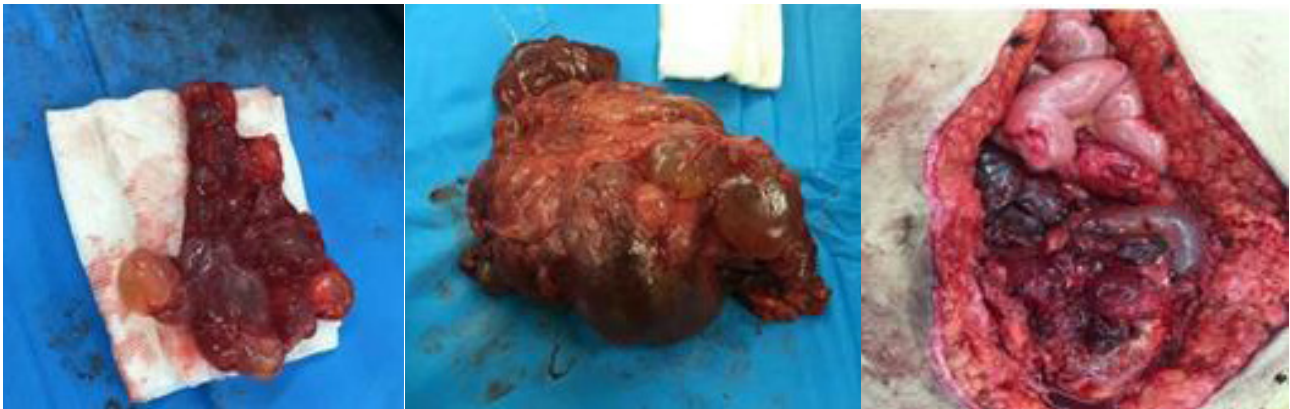

Figure 2. Pictures display tumor mass before and after surgical resection

DISCUSSION:

BMPM was first described in 1928 by Plaut, who incidentally observed loose pelvic cysts during an operation for uterine leiomyoma⁴. Fewer than 200 cases had been reported worldwide until 2017⁵. This disease is a rare medical entity and there are challenges in determining its origin, pathogenesis, diagnosis and therapy⁶. The tumor arises from epithelial and mesenchymal elements of the mesothelium surrounding the serous cavity. The biological behavior of BMPM is characterized by its slow growth and high rate of recurrence after surgical resection (approximately 50%)⁷. Also, these tumors do not have a high malignant transformation rate⁸. There are only two case reports of malignant transformation⁹.

Some authors believe that this pathologic condition appears with neoplastic changes, while others believe it is a reactive process which causes hyperplastic and dysplastic transformation as a response to inflammation, surgery, endometriosis, uterine leiomyoma or anything that could stimulate the peritoneal layer^{3,10,11}. According to a hormonal hypothesis, BMPM development is linked to sex hormone sensitivity. This theory seems to be supported by the higher incidence rate in reproduc-

tive-aged women than in men or children¹².

The most common symptoms are chronic or intermittent abdominal or pelvic pain with a palpable mass⁷. Since BMPM is a rare condition, it is hard to differentiate this condition from other benign and malignant conditions before surgical resection and pathologic study. Differential diagnoses include lymphangioma, mesenteric or omental cysts, visceral cysts, cystic adenomatoid tumors, pneumatosis cystoides intestinalis, pseudomyxoma peritonei and malignant mesothelioma^{7,13}. C.T scan, magnetic resonance imaging and aspiration cytology are useful in pre-operative diagnosis¹⁵. The only treatment for this lesion is surgery. We treated this patient with exploratory laparotomy and cytoreductive surgery.

Due to its benign nature, adjuvant chemotherapy and/or radiotherapy are not indicated in these patients. Other treatments such as hormonal therapy (anti-estrogens and gonadotropin-releasing analogues), sclerotherapy and hyperthermic intraperitoneal chemotherapy (HIPEC) have not proven the effect^{7,15}. In the year 2006, Wang TB and his team used the same method to treat this lesion⁷. In 2010, Cha KS performed laparoscopic surgery for a 47-year-old woman suffering from BMPM after

ovarian cystectomy and adhesiolysis by laparotomy¹⁵. In clinical practice, this tumor is sporadic and a high degree of suspicion is necessary for definite diagnosis and appropriate treatment.

ACKNOWLEDGMENT:

We thank our medical students from the ABC research Team at Zanjan University of Medical Sciences, Nاستاران Ghadimi and Mahyar Azizzadegan, for helping us.

REFERENCES:

1. Sugarbaker PH, Acherman YI, Gonzalez-Moreno S, Ortega-Perez G, Stuart OA, Marchettini P, Yoo D: Diagnosis and treatment of peritoneal mesothelioma: the Washington Cancer Institute experience. *Semin Oncol.* 2002, 29: 51-61.
2. Wong WL, Johns TA, Herlihy WG, Martin HL. Best cases from the AFIP: multicystic mesothelioma. *Radiographics.* 2004;24(1):247-50.
3. Kurisu Y, Tsuji M, Shibayama Y, Yamada T, Ohmichi M. Multicystic mesothelioma caused by endometriosis: 2 case reports and review of the literature. *Int J Gynecol Pathol.* 2011;30(2):163-6.
4. Dzieńiecka M, Kaluzynski A. Benign multicystic peritoneal mesothelioma (BMPM) - case report and review of the literature. *Pol J Pathol.* 2011;62(2):122-4.
5. Khurram MS, Shaikh H, Khan U, Edens J, Ibrar W, Hamza A, et al. Benign Multicystic Peritoneal Mesothelioma: A Rare Condition in an Uncommon Gender. *Case Rep Pathol.* 2017;2017:9752908.
6. Pitta X, Andreadis E, Ekonomou A, Papachristodoulou A, Tziouvaras C, Papapoulou L, et al. Benign multicystic peritoneal mesothelioma: a case report. *J Med Case Rep.* 2010;4:385.
7. Wang TB, Dai WG, Liu DW, Shi HP, Dong WG. Diagnosis and treatment of benign multicystic peritoneal mesothelioma. *World J Gastroenterol.* 2013;19(39):6689-92.
8. Safioleas MC, Constantinos K, Michael S, Konstantinos G, Constantinos S, Alkiviadis K. Benign multicystic peritoneal mesothelioma: a case report and review of the literature. *World J Gastroenterol.* 2006;12(35):5739-42.
9. Gonzalez-Moreno S, Yan H, Alcorn KW, Sugarbaker PH. Malignant transformation of "benign" cystic mesothelioma of the peritoneum. *J Surg Oncol.* 2002;79(4):243-51.
10. Takemoto S, Kawano R, Honda K, Nakazono A, Shimamatsu K. Benign multicystic peritoneal mesothelioma mimicking recurrence of an ovarian borderline tumor: a case report. *J Med Case Rep.* 2012;6:126.
11. Husain A, Ozdemirli M. Benign multicystic mesothelioma with concurrent colonic adenocarcinoma: a report of two cases. *Surg Today.* 2012;42(10):978-82.
12. Occhionorelli S, Tartarini D, Pascale G, Maccatrozzo S, Stano R, Vasquez G. Benign multicystic mesothelioma of peritoneum complicating acute appendicitis in a man: a case report. *J Med Case Rep.* 2016;10:44.
13. Snyder JA, Carman R, Jr., Aggon AA, Cardinale JP. Benign multicystic peritoneal mesothelioma: A rare case presenting as pneumoperitoneum and pneumatosis intestinalis. *J Gastrointest Oncol.* 2011;2(1):55-8.
14. Van Ruth S, Bronkhorst MW, Van Coevorden F, Zoetmulder FA. Peritoneal benign cystic mesothelioma: a case report and review of the literature. *European Journal of Surgical Oncology (EJSO).* 2002 Mar 1;28(2):192-5.
15. Cha KS, Choi YH, Lee YS, Park EK. Benign multicystic peritoneal mesothelioma treated with laparoendoscopic single site surgery: a case report and review of the literature. *Obstetrics & gynecology science.* 2018 Jan 1;61(1):170-4.