

## Pectoralis Major Myocutaneous Flap Reconstruction with Deltopectoral Flap Incision in the Surgical Treatment of Oral Cancer

Mohammad M Davudov<sup>1,2\*</sup>, Iraj Harirchi<sup>1</sup>, Zoheir Mirzajani<sup>1,2</sup>

### ABSTRACT

96

1. Tehran University of Medical Sciences, Cancer Research Center, Tehran, Iran
2. Azerbaijan Medical University, Department of Oral and Maxillofacial Surgery, Baku, Azerbaijan

**\*Corresponding Author:**

Mohammad M Davudov, MD  
Department of Oral and Maxillofacial Surgery, Azerbaijan Medical University, Baku, Azerbaijan.  
Tel: (+994)506258883  
Email: mahammad\_davud@mail.ru

**Background:** One of the main goals of patient management is the reconstruction of tissue defects following surgical resection for oral cancer. A variety of flaps used for this purpose, the most frequent being a Pectoralis Major Myocutaneous Flap (PMMF). This flap is currently widely used for the reconstruction of different defects of the head and neck.

**Methods:** Surgical resection of the primary tumor, as well as neck dissection, performed on 29 patients with oral squamous cell carcinoma between 2011–2017 in City Hospital #1 and Surgical Training Clinic of Azerbaijan Medical University. PMMF used for the reconstruction of defects using a deltopectoral flap incision.

**Results:** In 22 patients (75.8 %) primary healing occurred following a PMMF. Four patients (13.8 %) suffered PMMF necrosis and were taken back to the operating room for secondary reconstruction with a deltopectoral flap. In three patients (10.3%) the skin of the flap underwent necrosis, resulting in the development of an orocutaneous fistula.

**Conclusion:** Use of PMMF with deltopectoral flap incision enables deltopectoral flap availability. This flap can then be used early on or if PMMF fails.

**Keywords:** Pectoral Major Myocutaneous Flap, Deltopectoral flap, Reconstruction, Oral cancer



2019; 11(2):96-102

www.bccrjournal.com

**INTRODUCTION:**

**D**ue to the extensive resections that sometimes occur in the surgery of oral cavity tumors, one of the crucial elements of treatment is the reconstruction of formed defects. The closure of defects requires the use of various flaps. Pectoralis Major Myocutaneous Flap (PMMF) has some advantageous Properties in comparison with other flaps<sup>1</sup>.

The Pectoralis Major Myocutaneous Flap is one of the most commonly used flaps for the reconstruction of various defects in the head and neck area. This flap has many distinct advantages, such as repair of the surgical defect following resection and protecting the carotid artery in the neck with its muscular components. These properties make this flap a popular one in the repair of surgical defects<sup>2</sup>.

Besides the advantages of PMMF, there are some disadvantages reported in the literature, such as one that is related to its enormous bulk. During surgery and afterward, the Vascular pedicle that feeds the flap may be injured, leading to necrosis<sup>3</sup>.

In these cases, it is important to replace the flap to reconstruct the defect. The new flap will need to acquire from a new surgical area, and therefore requires a new incision. All this creates more scar tissue in the body and affects the overall health and psychological status of the patient.

This method combines all of the abovementioned issues by making an incision for both the PMMF and the Deltopectoral flap. The pectoralis major flap is then combined with a deltopectoral flap. This can be performed simultaneously or at different stages, if necessary<sup>4</sup>.

This approach has several advantages; namely that the Deltopectoral flap is a random flap which is less likely to undergo necrosis; also, a single incision is used for the PMMF and Deltopectoral flap, creating new surgical area for the Deltopectoral flap if necessary. The purpose of this study is to evaluate the reliability and indications for use of this flap in reconstructive head and neck surgeries.

**METHODS:**

Surgical resection of the primary tumor and neck dissection performed on 29 patients with squamous cell carcinoma of the oral cavity with subsequent PMMF reconstruction between 2011 –2017 in City Hospital N#1 and the Surgical Training Clinic of Azerbaijan Medical University.

**Inclusion Criteria**

Age group: 30-80-year-old patients with locally advanced oral squamous cell carcinoma.

**Exclusion Criteria**

Patients with T1-T2 and those who did not undergo neck dissection we excluded from the study.

**Table 1. Patient Data by Primary Tumor Localization and Tumor Size**

Localization of Primary Tumor	Size of Primary Tumor	Number of Patients
Squamous Cell Carcinoma of Retromolar Trigone	T3	5
Squamous Cell Carcinoma of Floor of Mouth	T3 –T4	14
Squamous Cell Carcinoma of Oral Tongue	T3 –T4	4
Squamous Cell Carcinoma of Buccal Mucosa and Gingiva	T4	6
<b>Total</b>		<b>29</b>

A Deltopectoral flap incision was made for all patients before lifting. The skin incision is designed as a lower limb of a deltopectoral flap, from the lateral edge of the pectoralis skin island to the anterior axillary fold (**Figure 1**).

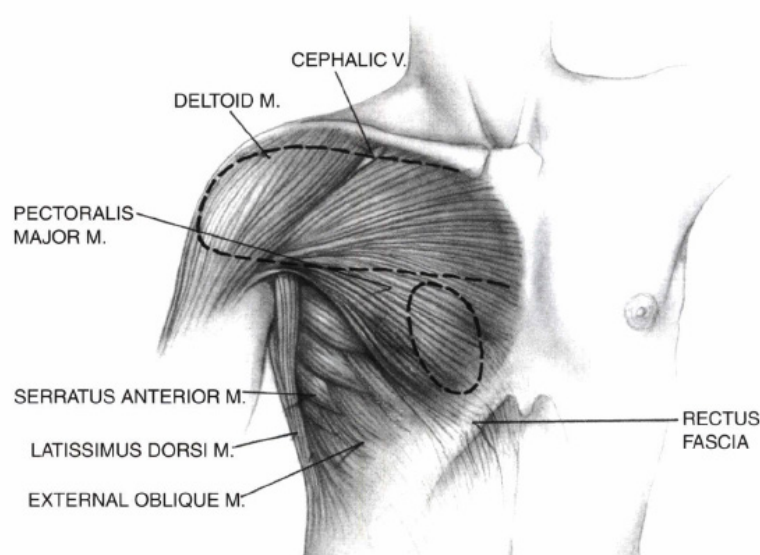
The Pectoralis Major muscle derives its blood supply from the pectoral branch of the thoracoacromial artery and lateral thoracic artery. After dissecting the flap of the chest wall, a subcutaneous tunnel formed under the skin between the neck and chest and the flap passed underneath the skin bridge. The flap is placed into the defect and sutured in two layers.

The donor defect closed primarily. Prophylactic antibiotic therapy and prophylactic anticoagulation used in all patients before and after surgery.

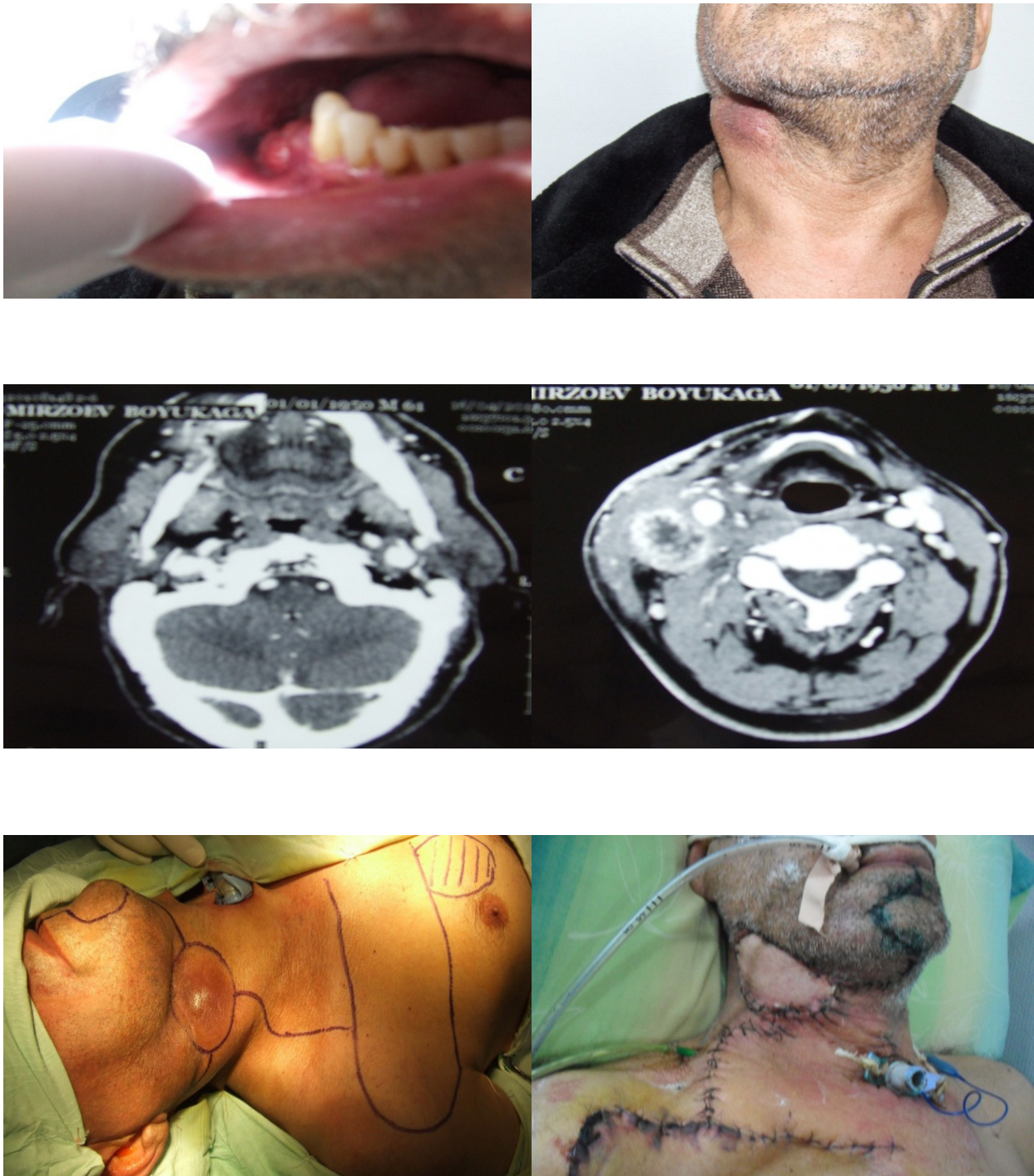
## RESULTS:

In 22 patients (75.8 %) PMMF recovered primarily. Four patients (13.8 %) suffered from PMMF necrosis

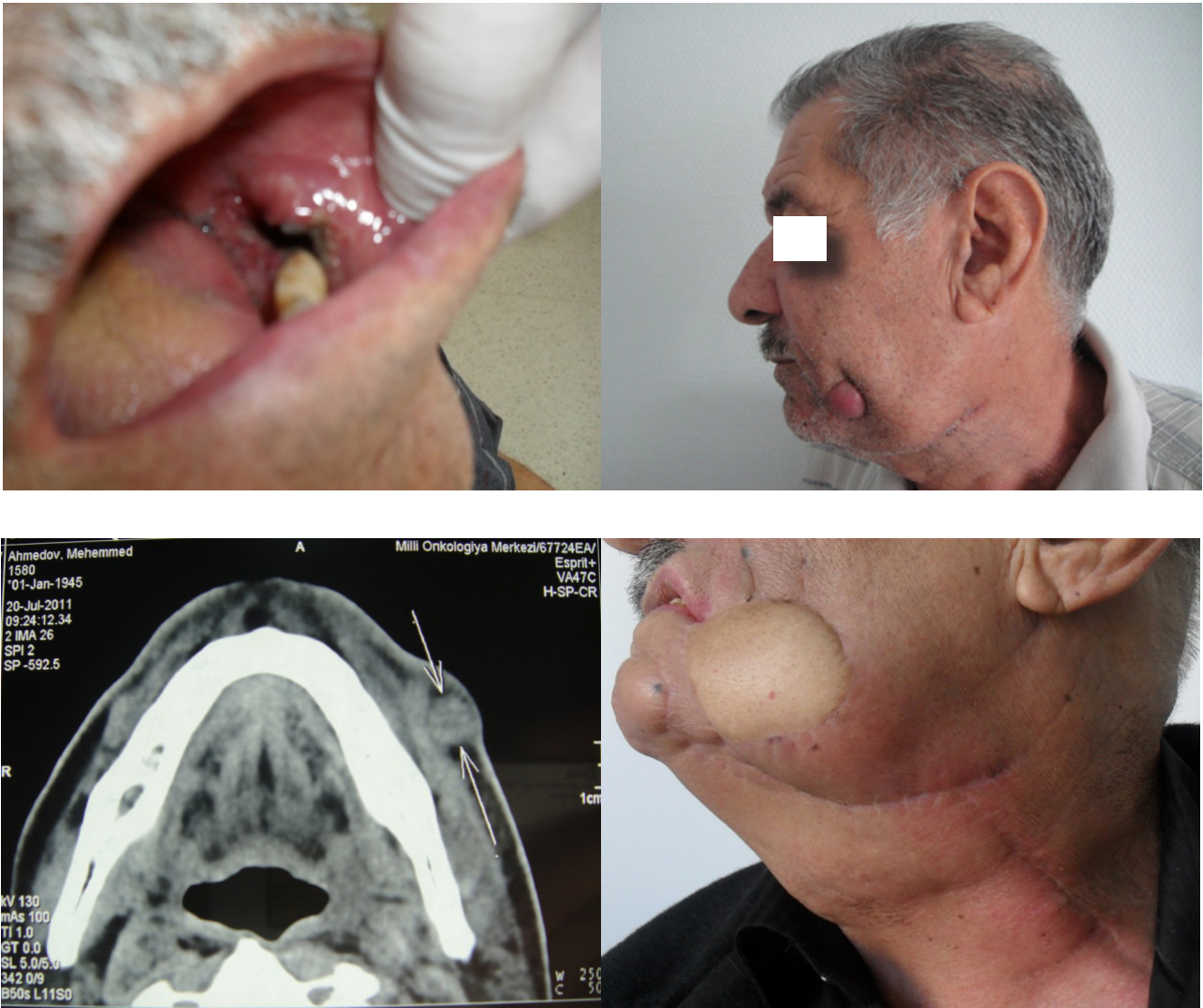and took back to the operating room. In three patients (10.3%) necrosis of the skin part of the flap developed and an Orocutaneous fistula formed. Two of the patients with PMMF necrosis had SCC of the floor of the mouth, one patient had SCC of the retromolar trigone, and another had SCC of the buccal mucosa. One of the patients with SCC of the floor of mouth underwent marginal resection of the mandible, in another patient, the integrity of the mandible protected. A reconstruction plate used for rebuilding and protection of the mandible. Total necrosis of PMMF found in a patient with neck metastasis of primary cancer of unknown origin. The purulent inflammation of the recipient wound area was the primary cause of necrosis. This patient underwent three months of radiotherapy before surgery. On postoperative day 5, five patients had necrosis and necrectomy was performed to avoid infectious complications. Deltopectoral flap lifting performed in the third week following necrectomy and liquidation of infec-



**Figure 1:** The pectoral mayor flap combined with deltopectoral flap (AN ATLAS OF HEAD AND NECK SURGERY, FOURTH EDITION-Lore & Medina)



**Figure 2:** Patient with T4N3M0 SCC of the gingiva. Reconstruction of neck defect using PMMF after resection of the primary tumor (with mandible segment resection) and comprehensive Radical neck dissection (with skin resection).



**Figure 3.** Patient with T4N1M0 SCC of buccal mucosa (involving skin part). Reconstruction with PMMF through defect of buccal space after surgical resection of the primary tumor (with skin part – total resection).

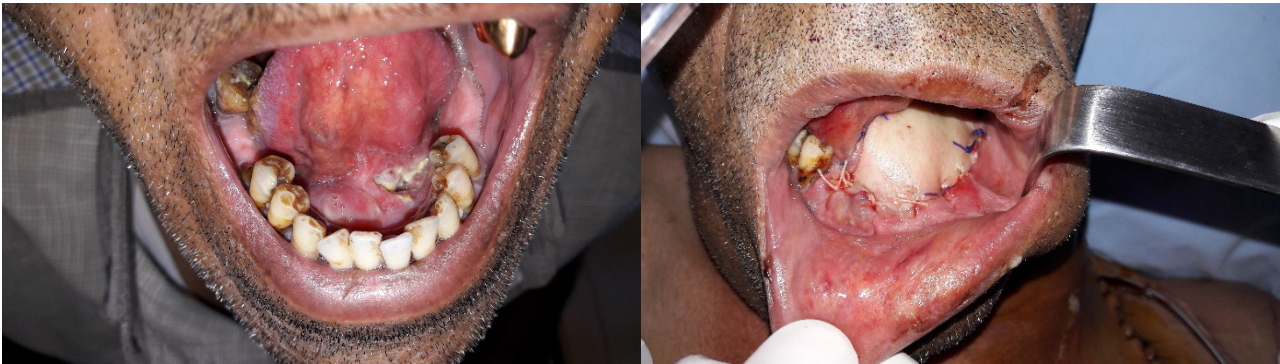tion. The skin pedicle of the deltopectoral flap resected in the third week after flap transfer. The Deltopectoral flap recovered primarily and the Orocutaneous fistula eliminated in all three patients.

### DISCUSSION:

This brief experience confirms the reliability of PMMF for head and neck reconstruction, as reported in the lit-

erature<sup>3-10</sup>. Its benefits include excellent viability and reliability of the flap due to its rich blood supply. Large skin defects can be easily covered, along with primary closure of the donor site<sup>11</sup>. The only flap loss occurred from a surgical misadventure.

Experience with the use of a rib graft has not been favourable. This conforms with other reports. Baek et al<sup>5</sup>. reported 2 losses in 5 patients with ostemyocuta-



**Figure 4.** Patient with T3N1M0 SCC of the floor of mouth after resection of the primary tumor with marginal mandibulectomy and reconstruction using PMMF.

neous flaps and Ariyan<sup>1,2,11</sup> also suffered 2 losses in 5 cases in which the rib was used. An additional advantage of PMMF is the muscular cover provided by the pedicle to the bare carotid vessels following neck dissection, thus greatly diminishing the incidence of carotid blow-out<sup>2</sup>.

The whole procedure can accomplish in a single stage; the donor area can be closed primarily in the majority of cases with an insignificant cosmetic or functional deficit. Previously, major ablative procedures in the head and neck required lengthy and multi-stage procedures, and also created cosmetic problems in donor areas. PMMP represents a transformation of that unhappy situation<sup>4</sup>. PMMF is more convenient due to its anatomical features and the technique is not difficult to learn. The use of this flap strongly recommended for moderate sized defects of the oral cavity, lower face and neck.

Many authors argue that considering the current panorama of head and neck reconstructions, the new approach is the use of the free flap. Despite this fact, PMMF remains an important tool for complex reconstruction of head and neck defects<sup>7-9</sup>, especially in medical centers where free flaps are not routinely available<sup>12</sup>.

Therefore, during the most complex reconstructions

(e.g., mandible resections involving the chin or craniofacial resections), priority is given to pedicle flaps. It is common knowledge that the PMMF is a reliable and versatile flap for head and neck reconstructions. It is the most important reconstruction tool when microvascular reconstruction is not available and is very useful in elderly patients or those with poor clinical conditions. Deganello et al<sup>8,13</sup>. showed that compared to using alternative non-microvascular techniques in high-risk patients, the PMMF is functionally and oncologically sound, and can even be cost-effective. Even if it is one of the most commonly used flaps by the head and neck surgeons, there is still much controversy about factors that lead to complications and thus to worse outcomes following the use of PMMF<sup>3-10, 12-14</sup>. Orocutaneous and pharyngeal cutaneous fistulas are among these complications. We chose to focus on these fistulas in this study because of their high impact on morbidity.

The incidence of complications with these flaps varies from 16% to 62% as reported in the medical literature. Total necrosis of the flap is rare, and partial loss of the flap can conservatively be managed. Shah et al. reported that in most cases, complications were treated conservatively, while in 26% of cases, additional surgical

procedures were required and only 2 patients needed a revision flap<sup>17</sup>.

During the last decade, there have been reports on the use of the internal mammary artery perforator flap (IMAP) for head and neck reconstructions. IMAP is a reliable pedicle flap with a wide rotation arc that can be used for cutaneous, pharyngeal and tracheostomal reconstruction. Therefore, it is becoming another essential tool for the head and neck surgeon<sup>4,10,14</sup>.

## CONCLUSIONS:

Despite all the disadvantages of the pectoral major muscle cutaneous flap and increased use of microvascular reconstruction, PMMF flap is still an acceptable method and has many advantages. It is fast, reliable and provides safe repair and is indicated, especially where tissue bulk is needed. The use of PMMF with a concurrent deltopectoral flap incision ensures the further availability of the deltopectoral flap that can be used early on, or in the event of PMMF failure.

## REFERENCES:

1. Ariyan S. The pectoralis major myocutaneous flap. The versatile flap for reconstruction in head and neck. *Plast. Reconstr. Surg.*, 1979;63:73-81.
2. Ariyan S. Further experiences with the pectoralis major myocutaneous flap for the immediate repair of defects from excisions of head and neck cancers. *Plastic and Reconstructive Surgery*. 1979 Nov;64(5):605-12.
3. Baek SM, Lawson W, Biller HF. An analysis of 133 pectoralis major myocutaneous flaps. *Plastic and reconstructive surgery*. 1982 Mar;69(3):460-9.
4. Ossoff RH, Wurster CF, Berktold RE, Krespi YP, Sisson GA. Complications after pectoralis major myocutaneous flap reconstruction of head and neck defects. *Archives of Otolaryngology*. 1983 Dec 1;109(12):812-4.
5. Friedrich W, Lierse W, Herberhold C. Myocutaneous vascular territory of the thoracoacromial artery. A topographical and morphometric study of the arterial vascularization of the pectoralis major myocutaneous flap. *Acta anatomica*. 1988;131(4):284-91.
6. Wilson JS, Ylacomettis AM, O'Neill T. Some observations on 112 pectoralis major myocutaneous flaps. *The American journal of surgery*. 1984 Feb 1;147(2):273-9.
7. Brusati R, Collini M, Bozzetti A, Chiapasco M, Galioto S. The pectoralis major myocutaneous flap: Experience in 100 consecutive cases. *Journal of Cranio-Maxillofacial Surgery*. 1988 Jan 1;16:35-9.
8. Robertson MS, Allison RS. The pectoralis major muscle in head and neck reconstruction. *Australian and New Zealand Journal of Surgery*. 1986 Oct;56(10):753-7.
9. Josepls CA, Gregor RT, Davidge-Pitts NJ, Waner M. The versatility of the pectoralis major myocutaneous flap. *Head Neck Surg*. 1985;7:365-8.
10. Mehrhof, A.I. Jr., Rosenstock, A., Neifeld, J.P., Merritt, W.H., Theogaraj, S.D. and Cohen, L.K. The pectoralis major myocutaneous flap in head and neck reconstruction. Analysis of complications. *Am.J.Surg.*, 1983;146:478-82.
11. Ariyan S. Reconstruction of the oropharyngeal area, in cancer of the head and neck.(Eds.): S. Ariyan, St. Louis and CV Mosby. 1987:285-98.
12. McLean JN, Carlson GW, Losken A. The pectoralis major myocutaneous flap revisited: a reliable technique for head and neck reconstruction. *Annals of plastic surgery*. 2010 May 1;64(5):570-3.
13. Milenović A, Virag M, Uglešić V, Aljinović-Ratković N. The pectoralis major flap in head and neck reconstruction: first 500 patients. *Journal of Cranio-Maxillofacial Surgery*. 2006 Sep 1;34(6):340-3.
14. Kekatpure VD, Trivedi NP, Manjula BV, et al. Pectoralis major flap for head and neck reconstruction in era of free flaps. *Int J Oral Maxillofac Surg* 2012;41:453-7. 4
15. Pinto FR, Malena CR, Vanni CM, Capelli FD, Matos LL, Kanda JL. Pectoralis major myocutaneous flaps for head and neck reconstruction: factors influencing occurrences of complications and the final outcome. *Sao Paulo Medical Journal*. 2010 Dec;128(6):336-41.
16. Dedivitis RA, Guimarães AV. Pectoralis major musculocutaneous flap in head and neck cancer reconstruction. *World journal of surgery*. 2002;26(1):67.
17. Mehta S, Sarkar S, Kavarana N, Bhatena H, Mehta A. Complications of the pectoralis major myocutaneous flap in the oral cavity: a prospective evaluation of 220 cases. *Plastic and reconstructive surgery*. 1996 Jul;98(1):31-7.