

Idiopathic retroperitoneal fibrosis: A case report and review of articles

Sanambar Sadeghi ^{1,*}, Mohsen Ayati ¹, Mohamad Ali Mohagheghi ¹, Shahriar Shahriaran ¹, Isa Jahanzad ¹, Somaye Safavi ¹

ABSTRACT

Idiopathic retroperitoneal fibrosis is a rare disorder of an unknown etiology characterized by an inflammatory proliferative fibrosing process that may involve the ureters in 80-100% of cases. The present study was carried on a 38 years old man who was admitted to Imam Khomeini Hospital with severe abdominal pain and renal failure. Abdominal MRI showed encasement of abdominal aorta and bilateral hydronephrosis. Tissue biopsy established the diagnosis of retroperitoneal fibrosis and ureteral obstruction was managed by insertion of bilateral ureteral stents. Presupposing the un-resectability, medical therapy was started. However he didn't show objective response to Prednisolone (1mg/kg) and had adverse effects. Subsequently, his disease was controlled by adding mycophenolate mofetil and azathioprine to reduce the steroid dose. After a few months, urinary stents were removed and he had been on complete remission for more than 4 years. Although advanced idiopathic retroperitoneal fibrosis would be effectively treated by a combination of ureteric stents and steroids, in difficult cases, second-line treatment with other immunosuppressive drugs may help to achieve long-term remission of disease.

Keywords: retroperitoneal fibrosis, ureteral obstruction, medical therapy.

فیروز رتروپریتونئال ایدیوپاتیک یک بیماری کمیاب با علت ناشناخته است که با فیروز پیش رونده التهابی با درگیری مجاری ادراری در ۸۰ تا ۱۰۰٪ موارد مشخص میشود. در این مطالعه یک مرد ۳۸ ساله که بدلیل درد شدید شکمی و نارسایی کلیه در بیمارستان امام خمینی بستری شد معرفی میگردد. در تصویربرداری MRI، محصور شدن آئورت شکمی و هیدرونفروز دو طرفه یافت گردید. در نمونه برداری بافتی تشخیص فیروز رتروپریتونئال محرز گردید و انسداد یورتر با قرار دادن استنت در مجاری ادراری درمان گردید. با فرض عدم قابلیت برداشت ضایعه به صورت جراحی، درمان طبی آغاز گردید. اما پاسخ قالب ملاحظه ای به پردنیزولون بمیزان یک میلیگرم به ازای هر کیلوگرم وزن مشاهده نگردید و عوارض این دارو ظاهر گردید. در ادامه، بیماری این فرد با افزودن میکوفنولات مفتیل و آزاتیوپرین همراه با کاهش دوز استروئید تحت کنترل درآمد. بعد از چند ماه استنت مجاری ادراری خارج شده و او بیش از چهار سال در بهبودی کامل به سر برد. اگرچه موارد پیشرفته فیروز رتروپریتونئال ایدیوپاتیک با قرار دادن استنت در مجاری ادراری همراه با تجویز استروئید بصورت موثری درمان میشود، در موارد مقاوم درمانهای خط دوم با داروهای سرکوب کننده سیستم ایمنی ممکن است به بهبودی طولانی مدت بیماری کمک کند.

واژه های کلیدی: فیروز رتروپریتونئال، انسداد یورتر، درمان طبی

Introduction

A “Retroperitoneal fibrosis is a clinical entity characterized by the progressive proliferation of connective tissue that may form a mass involving the periaortic area of abdomen.¹ Chronic periaortitis (CP) usually surrounds the abdominal aorta and iliac arteries and extends into the retroperitoneum that may envelop neighboring structures such as ureters and inferior vena cava.²

There are three subtypes of CP including inflammatory abdominal aortic aneurysms (IAAAS), peri-aneurismal retroperitoneal fibrosis (PRF), and idiopathic retroperitoneal fibrosis (IRPF).³

Most of the patients are known to have atherosclerosis and local inflammation against the antigens of the plaques,⁴ but depending on the series 10%-25% of cases have had an identified associated condition such as malignant diseases, infections, trauma, surgery or usage of certain drugs and abdomen radiotherapy.⁵ Although, IRPF was thought to result from a local inflammatory reaction to antigens it is frequently associated with constitutional symptoms and rising of acute phase reactants. Sometimes there is history of autoimmune diseases such as systemic lupus erythematosus, autoimmune thyroid disease, type 1 diabetes mellitus, myasthenia gravis and large vessel vacuities (giant cell arthritis, Takayasu arthritis).⁶

There are two main treatment approaches. Surgical relief of the obstruction by ureterolysis (open or laparoscopic) is the first choice. The second option consists of relieving the obstruction by placing ureteric stents, followed by corticosteroids alone or together with other immunosuppressant drugs.^{7, 8}

IgG4-related systemic disease is a newly recognized disorder that may manifest as retroperitoneal fibrosis. Assessing pathologic specimens for plasma cells, expressing IgG4, is useful in identifying patients with this disorder.⁷ Hyper-IgG4 disease is an important condition as the diagnosis can be verified by histology and simple blood tests. Treatment during the acute phase has a considerable outcome.⁹

We report a case of advanced IRPF who has pathologic criteria of IgG4-related disease successfully treated with immune-suppressive drugs.

Case Report

A 38 years old Caucasian man presented with sustained abdominal pain, bloating, nausea and weight loss. There wasn't any history of change in stool caliber or melena. He had been treated as a case of peptic ulcer over the prior 12 month interval in spite of normal upper GI endoscopy. Colonoscopy examination was normal as well.

On August 2006 the patient referred to emergency room with intractable vomiting due to uremic syndrome. Laboratory examination showed anemia (Hgb=10.5mg/dl), rise of creatinine (5.7) and hyperuricemia (uric acid=13.5). He treated with one occasion of hemodialysis. Results of other investigations were as follows: MCV=82, WBC=7000, platelet=280000, ESR=85, CRP=++++, ANA=negative, urine Banes Jones protein=negative, LDH=476 (upper of normal limit), liver function tests were normal; Iron=20, TIBC=287, reticulocyte=0.3%, calcium=8.7, ALK-PH=171u/l(80-306), and TSH=0.7mu/m(0.4-6). There was non-specific rise of immunoglobulin in serum protein electrophoresis. Serum albumin, amylase, AFP, BHCG, PSA level were normal. Bone marrow aspiration and biopsy showed reactive marrow without any evidence of malignant processes.

Kidney Doppler ultrasonography showed normal renal arteries and veins but bilateral hydronephrosis and nephrosclerotic changes. CT-Scan showed evidence of small retroperitoneal adenopathies, multiple opacities in both ureters and caliceal distention. Consultant urologist placed DJ-catheters in his ureters.

MRI revealed a retroperitoneal mass encasing abdominal aorta, IVC and both ureters extending from infra-renal artery level to aortic bifurcation. The mass was found to be diffusely hypo-intense on T1-weighted imaging and high intense on T2. Small lymph nodes were reported in the level of renal pedicles (**Fig 1, 2**). Differential diagnosis of the early needle-biopsy under the guide of sonography, he was referred to surgeon for open biopsy.

Laparotomy revealed fixed and ill-defined retroperitoneal mass. Pathology report of biopsied tissue showed fibrous tissue proliferation including broad anastomosing bands of hyalinized collagen infiltrated by numerous in

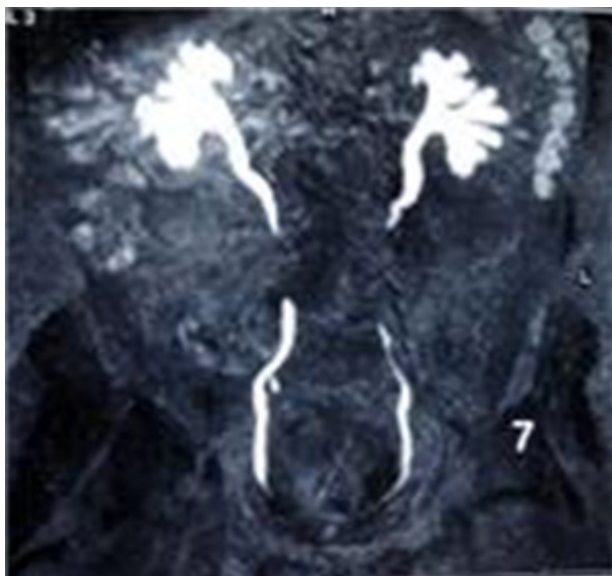


Figure 1 – Primary MRI showed periaortic mass and bilateral hydronephrosis, dilatation of proximal part of ureters, stenosis and replacement of medial part of ureters.

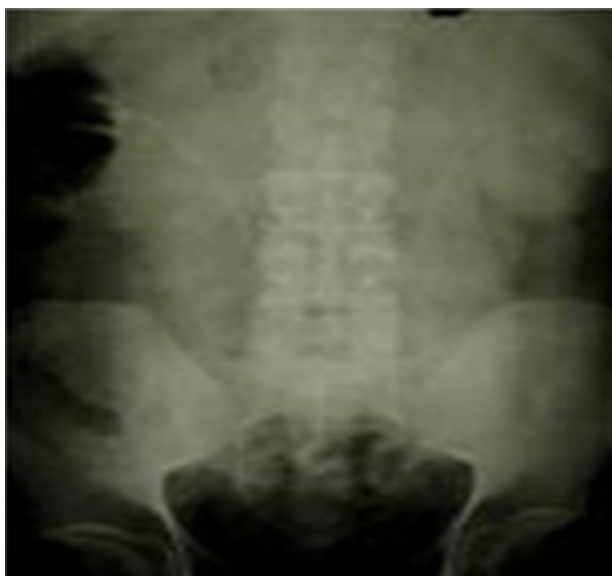

Figure 2 – KUB showed replacement of double J – catheters at the level of L3-L4.

flammatory cells embracing lymphocytes, plasma cells, histiocytes and smaller number of neutrophils. Occasional lymphoid nodules were also present. The process was diffusely infiltrated retroperitoneal adipose tissue. IHC stain for MSA showed small number of myofibroblast. Considering the clinical history and morphologic findings, diagnosis was quite compatible with IRPF (Fig 3a, b).

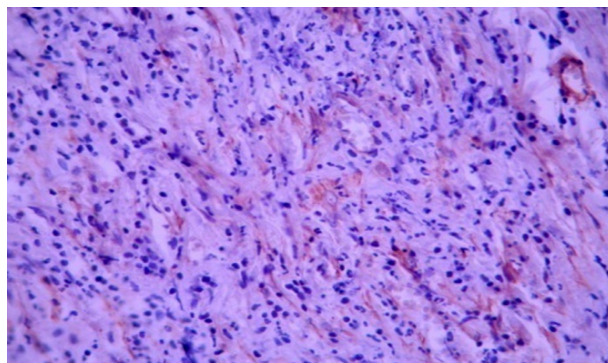


Figure 3 – Histopathology few number of myofibroblast.

The patient referred for counseling and management to Cancer Institute on Feb 2007. At the admission he was fit and well-nourished man who complained of sustained abdominal pain that was intractable to analgesic drugs. Medical history revealed he had hypertension and hyperthyroidism in past treated 20 years ago with ^{131}I . There was no history of abdominal trauma or surgery. He was under therapy with enalapril and levothyroxine. There was no history of betablocker, hydralazine, bromocriptine or ergotamine use. Physical examination was unremarkable except for abdominal distension. Blood pressure and body temperature was 150/90 & 36.7, respectively. Laboratory examination showed Hgb=11.5, BUN=21, Creatinine=1.7, ESR=85, CRP=+++ , serum IgG was 2100mg/dl (870-1700) and IgG4 was stained in pathology specimen (Fig 4). The high serum IgG concentration and highly positive IgG4 staining of biopsied tissue suggested the possible association with autoimmune pancreatitis. However there was no evidence of pancreatitis on physical or laboratory examinations and imaging.



Figure 4 –Positive staining for IgG4

Patient was treated first with prednisolone 0.5 mg/kg/day. The dose increased to 1 mg/kg after 2 weeks of no response. After six weeks ESR decreased to 50 mm but blood pressure, serum cholesterol and TSH increased. On March 2007 the dose of prednisolone decreased to 0.5 mg/kg/d and cyclosporine 100mg/bid was added to other prescribed drugs including Prednisolone, Omeprazole, Atorvastatin, Aspirin and Levothyroxine. On May 2007 CT-Scan and MRI revealed more than 30% decrease in the size of the mass (Fig 5, 6, 7).

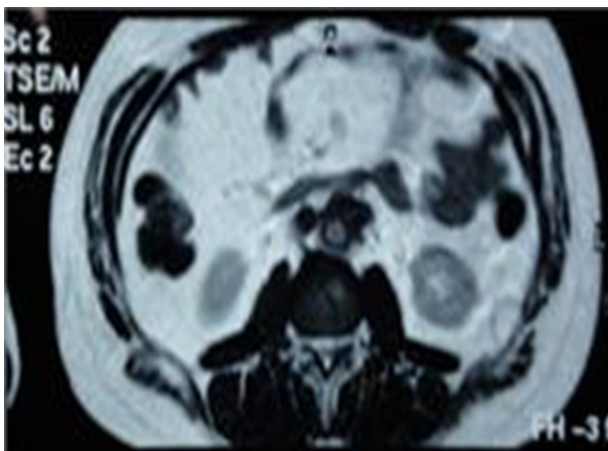
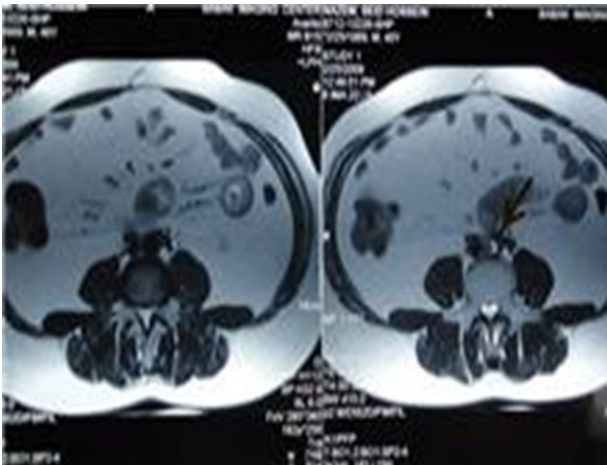


Figure 5 –MRI before treatment: evidence of hydronephrosis, and periaortic mass.

ESR decreased to 10 mm, Hgb raised to 14.2 mg/dl, Cr=0.7, BUN=13, Uric Acid=4.1, CRP-, TSH=2.5. Left and right DJ catheters were removed sequentially. The dose of prednisolone slowly tapered to 5 mg/d in the next six months. Cyclosporine changed to mycophenolate mofetil (CellCept)

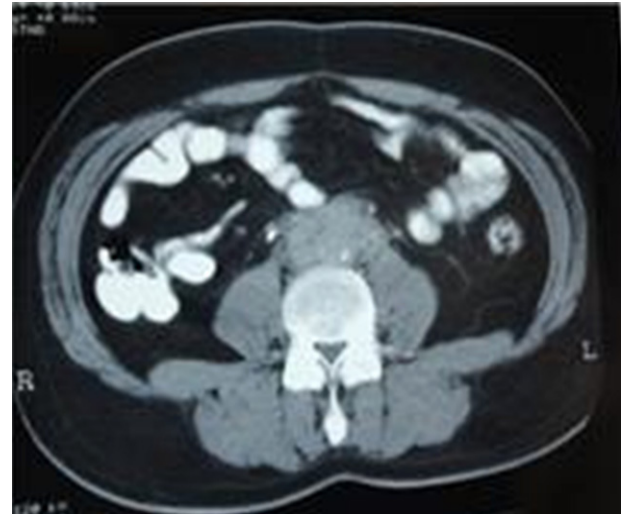

Figure 6 –CT-Scan before treatment: periaortic mass.

due to adverse events and few months later azathiopurine was added to other drugs. On Dec 2010, he was on CellCept 2 mg/daily, azathiopurine 50 mg/bid, prednisolone 5 mg/d and levothyroxine 50 mg/d. Furthermore, there wasn't hydronephrosis or progression of disease on CT scan (Fig 7).

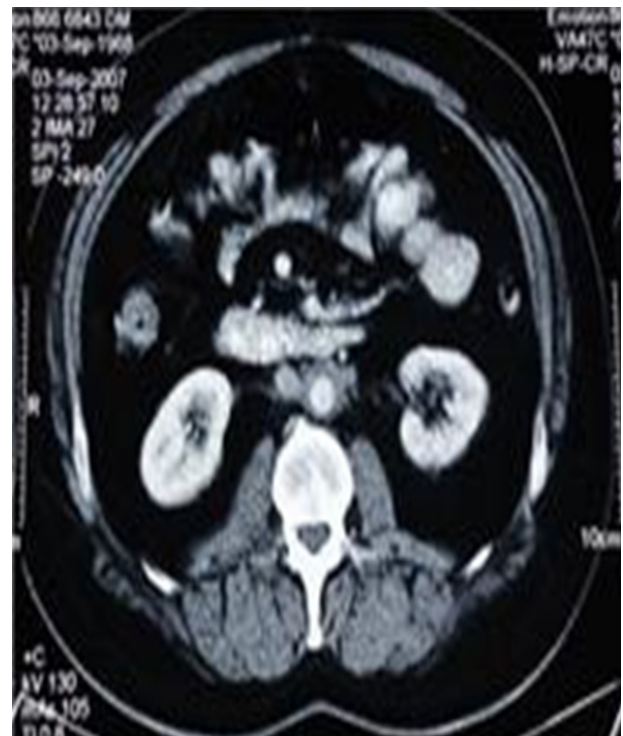

Figure 7 –CT Scan after treatment: Almost dissolving of whole retroperitoneal mass. Insignificant residue in anterior of aorta.

Discussion

The primary description of idiopathic retroperitoneal fibrosis (IRPF) is credited to the French urologist Albaran in 1905. But Ormand completely characterized the disease in 1984.⁹

Retroperitoneal fibrosis consists of chronic inflammation and marked fibrosis which often entraps the ureters and other abdominal organs.

There is considerable delay between the onset of symptoms and diagnosis which leads to the late complication of renal failure. Unfortunately our patient experienced the same scenario of longstanding non-specific symptoms leading to bilateral hydronephrosis and renal failure.

The mean age at onset of IRPF is 50-60. Although our patient age was lower and he was suffered from anemia and showed high ESR and CRP suggesting the presence of secondary disease, we couldn't find related systemic diseases. It should be noted that the above mentioned laboratory findings can arise in both idiopathic and secondary cases.³

Although radiation therapy is one of the causes of fibrosis, patient previous history of iodine therapy couldn't be the cause of his disease due to small dose he received. On the other hand, fibrosis is a local complication in the radiotherapy field and radiation induced fibrosis has mostly sclerotic bases than inflammatory reaction which our patient had (Fig 1).¹⁰

There is an association between IRPF and autoimmune diseases of thyroid.¹¹ We haven't had enough information about the patient previous thyroid problem, might be Graves' disease or an autonomous nodule in the base of multi-nodular goiter.

Currently there are no standardized criteria for the diagnosis of IRPF. Many physicians make the diagnosis based on clinical symptoms and cross-sectional imaging without biopsy or appropriate histological review.¹² However, several groups have reported that biopsy may actually change the diagnosis in 25% of cases; making interpretation of series without pathology misleading.¹³ Biopsy was used for confirmation of imaging findings. We also found aggregate of round mononuclear cells composed of B and T lymphocytes and a plasma cell infil-

trate. The plasma cells were IgG-bearing. These cells are involved in the pathogenesis of sclerosing pancreatitis, a disorder that sometimes is associated with IRPF.¹⁴⁻¹⁶

Although IRPF is a localized disease, constitutional symptoms and elevated acute-phase-reactants such as ESR and CRP, reduced hemoglobin and elevated gammaglobulin at presentation shows the inflammatory nature of the disease. Thick IgG4 bearing plasmacyte and dense fibrosis that accompanies healing wound appear to be a typical example of Th2-mediated pathology.^{17, 18} The importance of mentioned process is good response to glucocorticoids in the early management of IRPF.^{16,19,20} IRPF responds to corticosteroid initially but recurs without prolonged treatment. More recently, by addition the steroid-sparing agents such as mycophenolate mofetil, cyclophosphamide, and azathioprine or colchicines sustained remission have been attained.^{21,22} Our case is an example of successful long-term medical management of IRPF.

Conclusion

There are different attitudes in management of IRPF. The results of temporary ureteric stenting to relieve obstruction and protect renal function in addition to prescription of oral glucocorticoids and immunosuppressive drugs can alter the course of the inflammatory process. We found what was previously believed to be an uncommon and challenging syndrome, nowadays can be treated successfully with non-surgical approaches.

References

1. Vaglio A, Buzio C. Chronic periaortitis: a spectrum of diseases. *Curr Opin Rheumatol.* 2005 Jan;17(1):34-40.
2. Pipitone N, Salvarani C, Peter HH. [Chronic periaortitis]. *Internist (Berl).* 2010 Jan;51(1):45-52.
3. Vogt B, Meier P, Burnier M. [Retroperitoneal fibrosis, M. Ormand, periaortitis, ...?]. *Ther Umsch.* 2008 May;65(5):265-8.
4. Parums DV, Brown DL, Mitchinson MJ. Serum antibodies to oxidized low-density lipoprotein and ceroid in chronic periaortitis. *Arch Pathol Lab Med.* 1990 Apr;114(4):383-7.
5. Wolyniec W, Kozuchowska M, Sworczak K, Jezior D, Rozanska-Kluziak A, Rudka R, et al. When can we really diagnose idiopathic

- retroperitoneal fibrosis? *Nephrol Dial Transplant*. 2007 Jun;22(6):1786; author reply -7.
6. Vaglio A, Greco P, Corradi D, Palmisano A, Martorana D, Ronda N, et al. Autoimmune aspects of chronic periaortitis. *Autoimmun Rev*. 2006 Aug;5(7):458-64.
 7. Stifelman MD, Shah O, Mufarrrij P, Lipkin M. Minimally invasive management of retroperitoneal fibrosis. *Urology*. 2008 Feb;71(2):201-4.
 8. Moroni G, Gallelli B, Banfi G, Sandri S, Messa P, Ponticelli C. Long-term outcome of idiopathic retroperitoneal fibrosis treated with surgical and/or medical approaches. *Nephrol Dial Transplant*. 2006 Sep;21(9):2485-90.
 9. Ormond JK. Bilateral ureteral obstruction due to envelopment and compression by an inflammatory retroperitoneal process. *J Urol*. 1948 Jun;59(6):1072-9.
 10. Disel U, Alpay NR, Paydas S. Retroperitoneal fibrosis secondary to different etiologies (hemilaminectomy and hypothyroidism): reports of two cases. *Ren Fail*. 2007;29(5):639-46.
 11. Lee JE, Han SH, Kim DK, Moon SJ, Choi KH, Lee HY, et al. Idiopathic retroperitoneal fibrosis associated with Hashimoto's thyroiditis in an old-aged man. *Yonsei Med J*. 2008 Dec 31;49(6):1032-5.
 12. Surabhi VR, Menias C, Prasad SR, Patel AH, Nagar A, Dalrymple NC. Neoplastic and non-neoplastic proliferative disorders of the perirenal space: cross-sectional imaging findings. *Radiographics*. 2008 Jul-Aug;28(4):1005-17.
 13. Rodriguez Jornet A, Andreu Navarro FJ, Orellana Fernandez R, Ibeas Lopez J, Garcia Garcia M. [Idiopathic retroperitoneal fibrosis: clinico-pathological characteristics]. *Nefrologia*. 2009;29(4):298-303.
 14. Hamano H, Kawa S, Ochi Y, Unno H, Shiba N, Wajiki M, et al. Hydronephrosis associated with retroperitoneal fibrosis and sclerosing pancreatitis. *Lancet*. 2002 Apr 20;359(9315):1403-4.
 15. Yamamoto M, Takahashi H, Naishiro Y, Isshiki H, Ohara M, Suzuki C, et al. Mikulicz's disease and systemic IgG4-related plasmacytic syndrome (SIPS). *Nihon Rinsho Meneki Gakkai Kaishi*. 2008 Feb;31(1):1-8.
 16. Stone JR. Aortitis, periaortitis, and retroperitoneal fibrosis, as manifestations of IgG4-related systemic disease. *Curr Opin Rheumatol*. 2011 Jan;23(1):88-94.
 17. Neild GH, Rodriguez-Justo M, Wall C, Connolly JO. Hyper-IgG4 disease: report and characterisation of a new disease. *BMC Med*. 2006;4:23.
 18. Miura H, Miyachi Y. IgG4-related retroperitoneal fibrosis and sclerosing cholangitis independent of autoimmune pancreatitis. A recurrent case after a 5-year history of spontaneous remission. *JOP*. 2009;10(4):432-7.
 19. Duchene DA, Winfield HN, Cadeddu JA, Clayman RV, Gomella LG, Kavoussi LR, et al. Multi-institutional survey of laparoscopic ureterolysis for retroperitoneal fibrosis. *Urology*. 2007 Jun;69(6):1017-21.
 20. Fry AC, Singh S, Gunda SS, Boustead GB, Hanbury DC, McNicholas TA, et al. Successful use of steroids and ureteric stents in 24 patients with idiopathic retroperitoneal fibrosis: a retrospective study. *Nephron Clin Pract*. 2008;108(3):c213-20.
 21. Adler S, Lodermeier S, Gaa J, Heemann U. Successful mycophenolate mofetil therapy in nine patients with idiopathic retroperitoneal fibrosis. *Rheumatology (Oxford)*. 2008 Oct;47(10):1535-8.
 22. Swartz RD. Idiopathic retroperitoneal fibrosis: a review of the pathogenesis and approaches to treatment. *Am J Kidney Dis*. 2009 Sep;54(3):546-53.